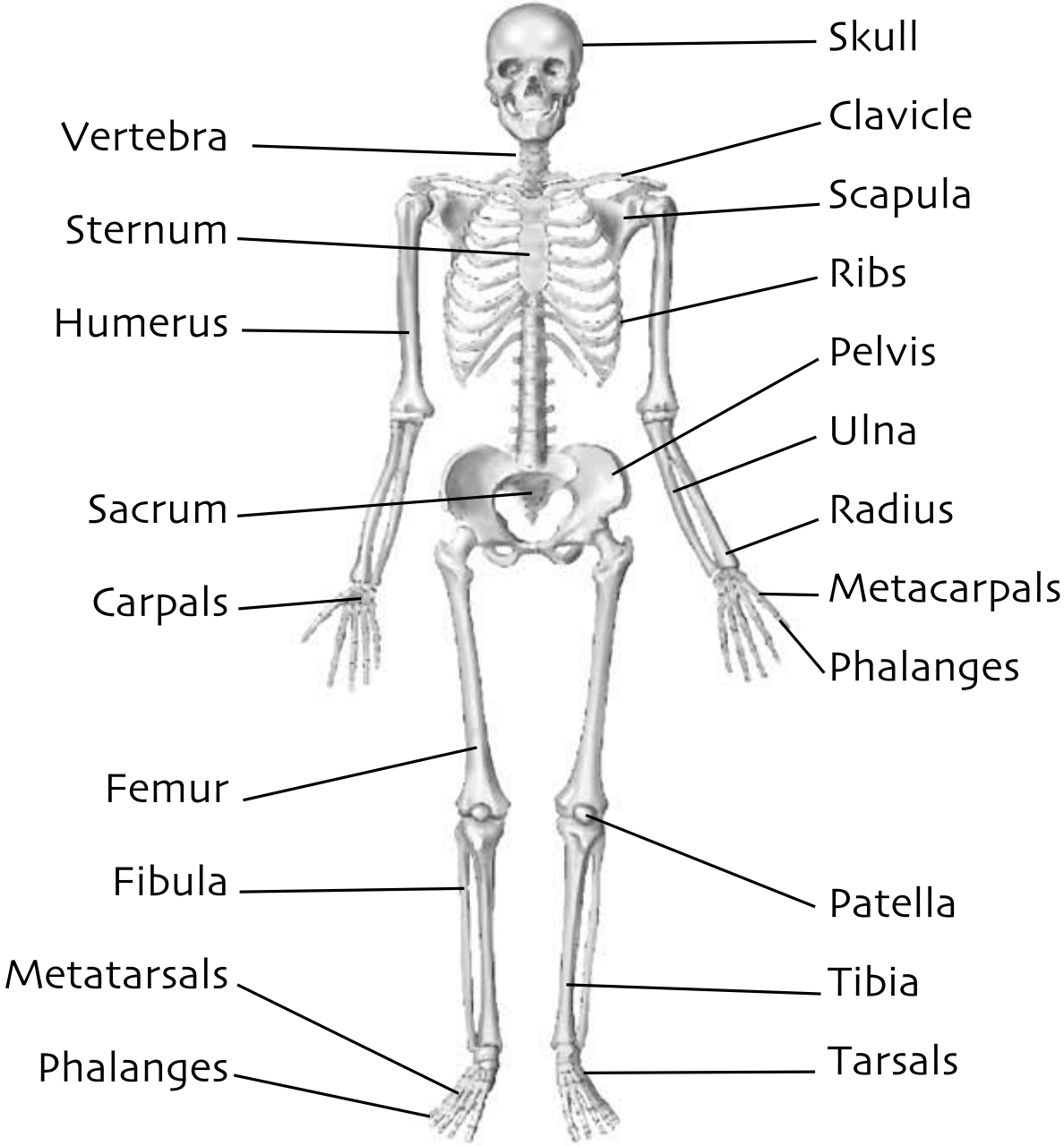
Skull
Clavicle
Vertebra
Scapula
Sternum
Ribs
Humerus
Pelvis
Ulna
Sacrum
Radius
Carpals
Metacarpals
Phalanges
Femur
Fibula
Patella
Metatarsals
Tibia
Phalanges
Tarsals